

# The Efficacy of Basivertebral Nerve Ablation on Chronic Low Back Pain: A Literature Review

Charlene Canales, DO<sup>1</sup>, Panayotis Jusakos, MD<sup>1</sup>, Daniel Sanchez, MD<sup>1</sup>, Michael Vincent Sposito, MD<sup>1</sup>, Suha Qasem, MD<sup>1</sup>

<sup>1</sup>One Brooklyn Health/Kingsbrook Jewish Medical Center - PM&R Residents

## Background

The basivertebral nerve ablation (BVNA) procedure has emerged as a promising minimally invasive treatment option for chronic low back pain, particularly in cases associated with degenerative disc disease. The procedure targets the basivertebral nerve, a sensory nerve that innervates the vertebral body, which is thought to play a role in the transmission of pain signals from the vertebral body. Using fluoroscopic guidance, a small needle is inserted into the vertebral body where the basivertebral nerve is located. Radiofrequency energy is then applied to ablate and destroy the nerve, interrupting the pain signals. The procedure is performed on an outpatient basis, typically under local anesthesia, and involves minimal disruption of surrounding tissues. Indications for this procedure includes patients with chronic low back pain unresponsive to conservative treatments (e.g., physical therapy, medications) and patients with chronic low back pain with evidence of Modic changes on MRI, suggesting degenerative changes in the vertebrae. Many patients report significant reductions in pain after the procedure, with effects that can last for several months to years. Patients often experience improvements in mobility and quality of life post-ablation.

## Methods

A comprehensive scientific literature search was conducted through specialized databases such as MEDLINE, EMBASE, CINAHL, PubMed, MedlinePlus, PsycINFO, and Cochrane Library. The search terms used to retrieve the relevant literature in each of these databases were "neuromodulation" AND "suprascapular nerve" AND "chronic shoulder pain".

## Results/Evidence Table

Study	Therapy or Exposure	Outcome/Results
Cohort Study	<ul style="list-style-type: none"> <li>- There were 95/113 (84%) BVNA patients who completed a 3-year visit across 22 study sites</li> <li>- At baseline, 71% of patients reported back pain for <math>\geq 5</math> years, 28% were taking opioids, 34% had spinal injections in the prior 12 months, and 14% had prior low back surgery</li> </ul>	<ul style="list-style-type: none"> <li>- Pain and functional improvements were significant at 3 years with a mean reduction in NPS of 4.3 points from 6.7 at baseline (95% CI 3.8, 4.8; <math>p &lt; 0.0001</math>) and a mean reduction in ODI of 31.2 points from 46.1 at baseline (95% CI 28.4, 34.0; <math>p &lt; 0.0001</math>). There was a 74% reduction in the use of opioids and 84% reduction in the use of the therapeutic spinal interventions from baseline to 3 years.</li> <li>- There were no serious device or device-procedure related adverse events reported through three years</li> <li>- Intraosseous BVNA demonstrates statistically significant, clinically meaningful, and durable improvements in pain and function through 3 years in patients with primary vertebrogenic low back pain and significantly reduced opioid use and interventions for low back pain.</li> </ul>
Longitudinal Study	<ul style="list-style-type: none"> <li>- 147 patients were treated with RF ablation of the BVN in a randomized controlled trial</li> <li>- Evaluations, including patient self-assessments, physical and neurological examinations, and safety assessments, were performed at 2 and 6 weeks, and 3, 6, 12, 18, and 24 months postoperatively</li> </ul>	<ul style="list-style-type: none"> <li>- The mean percent improvements in ODI and VAS compared to baseline at 2 years were 53.7 and 52.9%, respectively</li> <li>- Responder rates for ODI and VAS were also maintained through 2 years with patients showing clinically meaningful improvements in both: ODI <math>\geq 10</math>-point improvement in 76.4% of patients and ODI <math>\geq 20</math>-point improvement in 57.5%; VAS <math>\geq 1.5</math> cm improvement in 70.2% of patients</li> </ul>
Systematic Review	<ul style="list-style-type: none"> <li>- Individuals <math>\geq 18</math> years old with chronic nonradiating vertebrogenic pain</li> <li>- 11/286 article publications with extensive data on 413 participants matched the inclusion criteria and were used for this review</li> </ul>	<ul style="list-style-type: none"> <li>- At three months, a majority of the participants reported <math>\geq 10</math>-point improvement in the ODI, and <math>\geq</math> two-point improvement in the VAS</li> <li>- A good number of patients in the basivertebral nerve ablation (BVNA) arm reported complete pain resolution demonstrating therapy success and the superiority of BVNA over sham and standard treatment</li> </ul>
Systematic Review	<ul style="list-style-type: none"> <li>- Persons <math>\geq 18</math> years of age with chronic LBP associated with type 1 or 2 Modic changes</li> <li>- 12/856 publications met the inclusion criteria, with 414 participants allocated to receive BVN RFA</li> </ul>	<ul style="list-style-type: none"> <li>- Single-arm meta-analysis showed a success rate of 65% (95% confidence interval [CI] 51-78%) and 64% (95% CI 43-82%) for <math>\geq 50\%</math> pain relief at 6 and 12 months, respectively.</li> <li>- Rates of <math>\geq 15</math>-point ODI score improvement were 75% (95% CI 63-86%) and 75% (95% CI 63-85%) at 6 and 12 months, respectively</li> </ul>
Prospective Experimental Uncontrolled Trial	<ul style="list-style-type: none"> <li>- Performed percutaneous CT-guided BVN ablation in 56 consecutive patients presenting with vertebrogenic chronic LBP</li> <li>- Pre- and post-procedure pain and disability levels were measured using VAS and ODI</li> </ul>	<ul style="list-style-type: none"> <li>- At 3- and 12-month follow-up, VAS and ODI scores decreased significantly compared to baseline</li> <li>- Clinical success was reached in 54/56 patients (96.5%) for pain and 54/56 patients (96.5%) for disability</li> <li>- Percutaneous CT-guided intra-osseous BVA seems to be a safe, fast, and powerful technique for pain relief in patients with vertebrogenic chronic LBP, when the selection of patients is based on a multidisciplinary approach including both conventional Diagnostic Radiology and Nuclear Medicine imaging.</li> </ul>

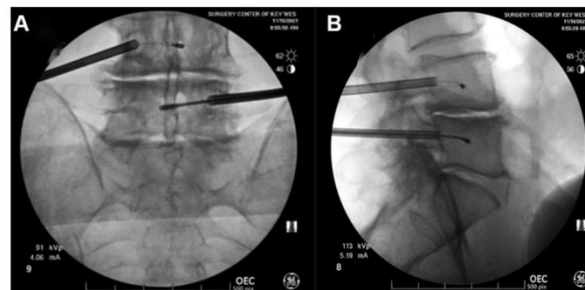


Figure 1. Representative fluoroscopic image of a BVNA procedure at the L4-L5 level. Front view (A), lateral view (B). BVNA: basivertebral nerve ablation.

## Discussion and Conclusions

These findings highlight the potential of the basivertebral nerve ablation procedure as a safe, effective and minimally invasive therapeutic option for chronic low back pain, particularly for patients unresponsive to conservative treatments. However, the studies were predominantly industry-funded or lacked patient diversity leading to generalizability issues. There is a need for more randomized controlled trial studies to reduce the risk of bias and to allow researchers to draw causal conclusions about the use of this procedure to treat of chronic low back pain.

## References

- Smuck, M., et al. Intraosseous basivertebral nerve ablation: Pooled long-term outcomes from two prospective clinical trials. *Interventional Pain Med.* 2023 Jun 10;2(2):100256
- Fischgrund, J., et al. Intraosseous Basivertebral Nerve Ablation for the Treatment of Chronic Low Back Pain: 2-Year Results From a Prospective Randomized Double-Blind Sham-Controlled Multicenter Study. *Int J Spine Surg.* 2019 Apr 30;13(2):110-119
- Nwosu, M., et al. The Effectiveness of Intraosseous Basivertebral Nerve Ablation in the Treatment of Nonradiating Vertebrogenic Pain: A Systematic Review. *Cureus.* 2023 Apr 4;15(4):e37114.
- Conger, A., et al. The Effectiveness of Intraosseous Basivertebral Nerve Radiofrequency Ablation for the Treatment of Vertebrogenic Low Back Pain: An Updated Systematic Review with Single-Arm Meta-analysis. *Pain Med.* 2022 Jul 20;23(Suppl 2):S50-S62
- De Vivo, A. E., et al. Intra-osseous basivertebral nerve radiofrequency ablation (BVA) for the treatment of vertebrogenic chronic low back pain. *Neuroradiology.* 2021 May;63(5):809-815