NYU Langone Health

Traumatic Lingual Neuralgia after Inferior Alveolar Block for Dental Work

Fellow: Shaharyar Ahmad, MD
Mentor: Aharon Benelyahoo, MD



Featured Speaker

Shaharyar Ahmad, MD
Pain Medicine Fellow
NYU Grossman School of Medicine

NYU Langone Health

No financial disclosures.

NYU Langone Health

Lingual Nerve Injury

- ✓ Complication of inferior alveolar nerve block, dental procedures
- ✓ Lingual nerve is unifascicular while inferior alveolar nerve is multifascicular

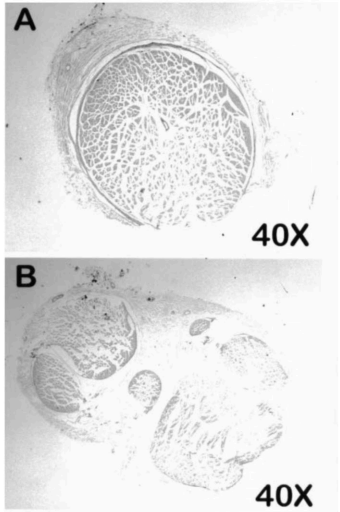

Figure. A composite figure of the lingual and inferior alveolar nerves from the same side of the same cadaver. The case is nerve number 3 in the table (hematoxylin and eosin stain X40). A. Monofascicular lingual nerve at lingula. B. Multifascicular (six fascicles) inferior alveolar nerve at lingula.

NYU Langone Health

Lingual Nerve Anatomy

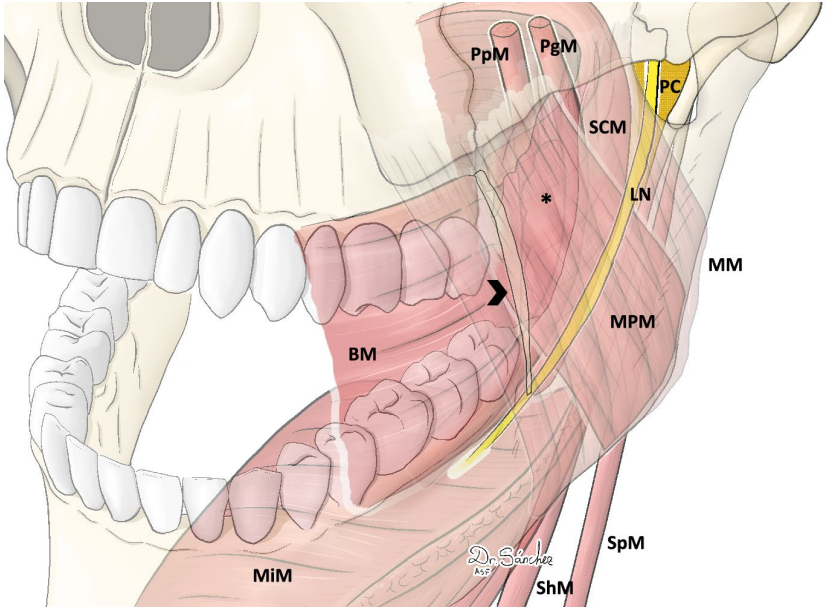

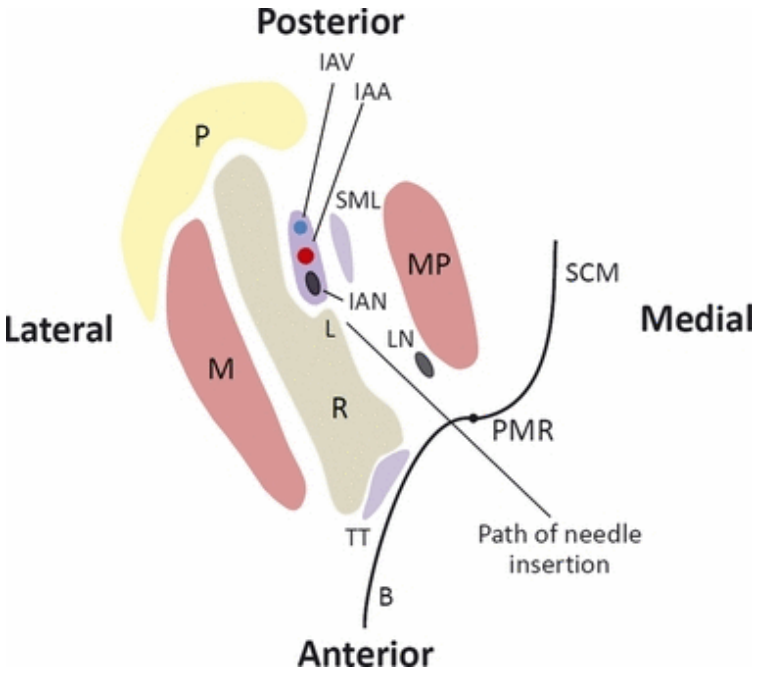

NYU Langone Health

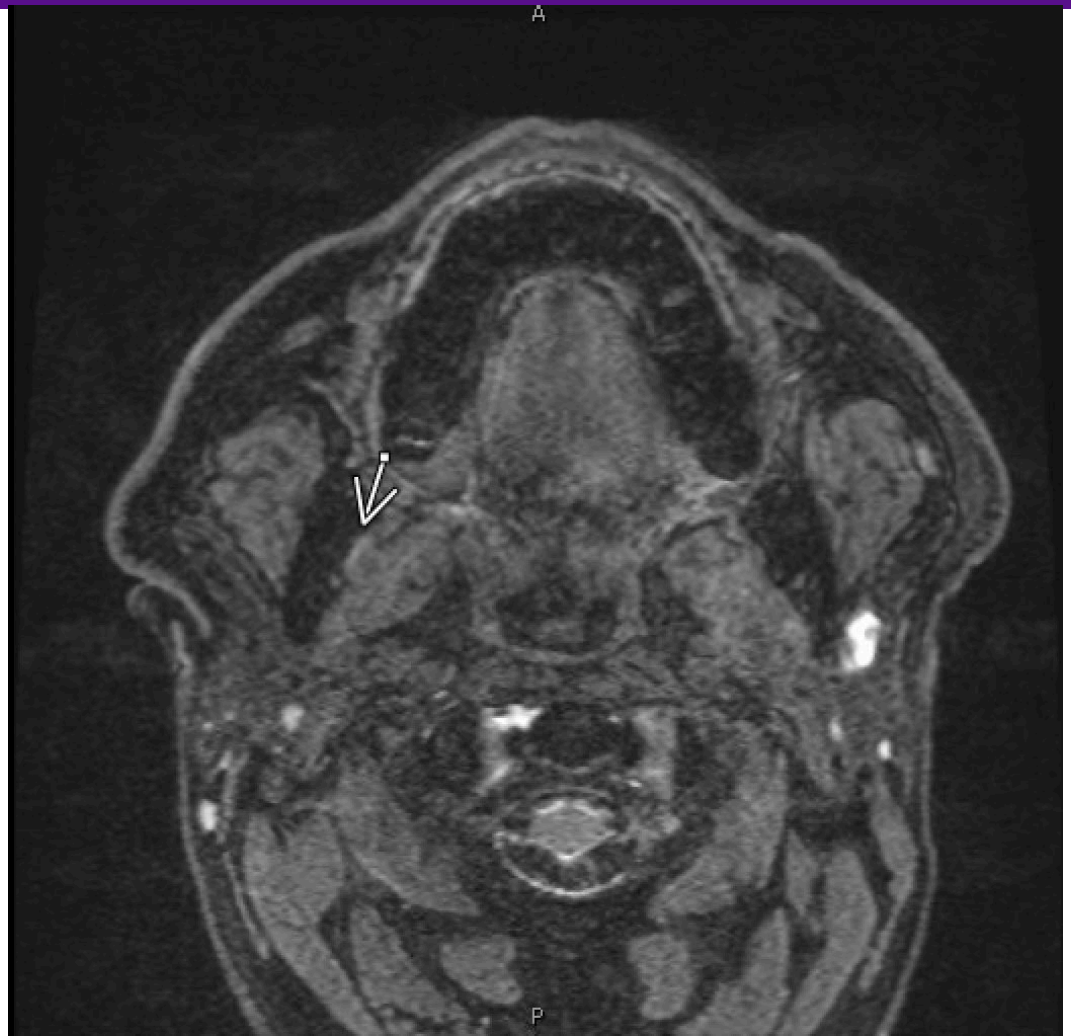

NYU Langone Health

57-year-old male presents with right-sided tongue pain

- Past medical history of Factor V Leiden on Eliquis
- Underwent tooth extraction six months ago when student dentist performed inferior alveolar and lingual nerve blocks
- Unable to eat, talk, or work as actor due to pain
- Pain is 5-7/10 in intensity, burning in character, non-radiating, and constant around right lingual distribution
- Was prescribed physical therapy, gabapentin dose increased to 1800mg/day

57-year-old male presents with right-sided tongue pain

- One-month follow-up
  - Improved right lateral tongue pain, able to talk and chew better
  - Burning pain now feels like pressure pain
  - Numbness and paresthesia over right lateral tongue
  - Had not started physical therapy due to tightness on floor of mouth
- Two-month follow-up
  - Unchanged numbness since last visit
  - Gabapentin reduced to 1200 mg/day due to sedation from previous dose

NYU Langone Health

Medication

- Corticosteroids
- Tricyclic antidepressants
- Anticonvulsants
  - Carbamazepine, oxcarbazapine
- Membrane stabilizers
  - Gabapentin, zonisamide, topiramate
- Topical agents
  - Clonazepam
  - 4% Lidocaine
  - EMLA

CLINICAL STUDY

Neuropathic Pain Due to Iatrogenic Lingual Nerve Lesion: Nerve Grafting to Reduce Otherwise Untreatable Pain

ELSEVIER

Available online at www.sciencedirect.com

SCIENCE DIRECT

Brain Research 1051 (2005) 1 – 7

BRAIN RESEARCH

www.elsevier.com/locate/brainres

Research Report

The effect of carbamazepine on injury-induced ectopic discharge in the lingual nerve

Julian M. Yates*, Keith G. Smith, Peter P. Robinson

Department of Oral and Maxillofacial Surgery, School of Clinical Dentistry, University of Sheffield, Claremont Crescent, Sheffield S10 2TA, UK

Accepted 13 May 2005
Available online 5 July 2005

Abstract

Previous studies have shown that the development of ectopic activity from damaged axons following nerve injury may contribute to the aetiology of sensory disturbances, including dysaesthesia. Pharmacological manipulation of this activity could provide a method of treatment for this intractable condition. In this study we have investigated the effect of carbamazepine, an anti-convulsant, as it is known to have membrane stabilising properties. In eight anaesthetised adult ferrets the left lingual nerve was sectioned and the animals allowed to recover for 3 days. Then, in terminal experiments under general anaesthesia, the nerve was re-exposed and electrophysiological recordings were made from spontaneously active units in fine filaments dissected from the nerve proximal to the injury site. Carbamazepine in a modified cyclodextrin (hydroxypropyl-β-cyclodextrin) was administered intravenously in increments, in order to achieve a progressively increasing systemic concentration, and serum levels were determined at the point that activity ceased. Twenty-one spontaneously active units were studied, with conduction velocities of 2.1–28.9 m s^{-1} and discharge frequencies of 0.25–15.3 Hz. Spontaneous activity ceased in 13 units with a serum concentration of carbamazepine ranging from 3.5 to 8.4 mg/l, which was within the normal therapeutic range (4–12 mg/l). Four units ceased activity with carbamazepine levels above the therapeutic range (15.4–17.2 mg/ml), but the remaining four continued to discharge throughout the recording period. These data suggest that systemic carbamazepine can reduce the level of spontaneous activity initiated in some axons following lingual nerve injury.

Theme: Excitable membranes and synaptic transmission
Topic: Sodium channels

Keywords: Carbamazepine; Ectopic discharge; Lingual nerve

Surgery

"Microsurgical repair of LN [lingual nerve] injury has the best chance of successful restoration of acceptable neurosensory function if done within 9 months of the injury."

Retrospective Review of Microsurgical Repair of 222 Lingual Nerve Injuries

Shahrokh C. Bagheri, DMD, MD, Roger A. Meyer, DDS, MD,† Husain Ali Khan, DMD, MD,‡ Amy Kuhmichel, DMD,§ and Martin B. Steed, DDS‖*

Purpose: Injury to the lingual nerve (LN) is a known complication associated with several oral and maxillofacial surgical procedures. We have reviewed the demographics, timing, and outcome of microsurgical

British Journal of Oral and Maxillofacial Surgery (2004) 42, 285–292

ELSEVIER

BRITISH Journal of Oral and Maxillofacial Surgery

www.bjoms.com

patients who had undergone
December 2005. A physical
ch patient preoperatively. All
rosensory testing repeated at
osensory testing results and
ale. The following data were
omplaint (numbness or pain,
gs, surgical procedure, and
ng to whether they achieved
scale, or had unsatisfactory or
ds ratios (OR) were used to
perating characteristic curve
ted the patient outcomes.

31.1 years, range 15 to 61)
nmon cause of LN injury was
ibular ramus osteotomy (n =
5%) or numbness with pain
(range 1.5 to 96). The most
vith neurorrhaphy (n = 154,
%). Nineteen patients (8.6%)
erve) for reconstruction of a
external decompression with
dysfunction (defined by the
omplete return of sensation")
55 patients with recovery to
rovement. Using the logistic
greater odds of improvement
ent decreased by 5.8%. The
ore than 9 months for repair

REVIEW

Current management of damage to the inferior alveolar and lingual nerves as a result of removal of third molars

Peter P. Robinson*, Alison R. Loescher, Julian M. Yates, Keith G. Smith

Department of Oral & Maxillofacial Surgery, School of Clinical Dentistry, University of Sheffield, Claremont Crescent, Sheffield S10 2TA, UK

Accepted 28 February 2004

Available online 12 May 2004

KEYWORDS
Inferior alveolar nerve;
Lingual nerve;
Nerve injury;
Nerve repair;
Sensory testing

Summary In this review we present algorithms to guide the clinical management of patients who sustain damage to the inferior alveolar or lingual nerves during the removal of lower third molars. Monitoring recovery using simple sensory testing allows those patients who may benefit from some form of intervention to be identified. There is good evidence that some surgical procedures produce worthwhile improvements in sensation but management of nerve injury-induced dysaesthesia remains problematic.

Lingual Nerve Block

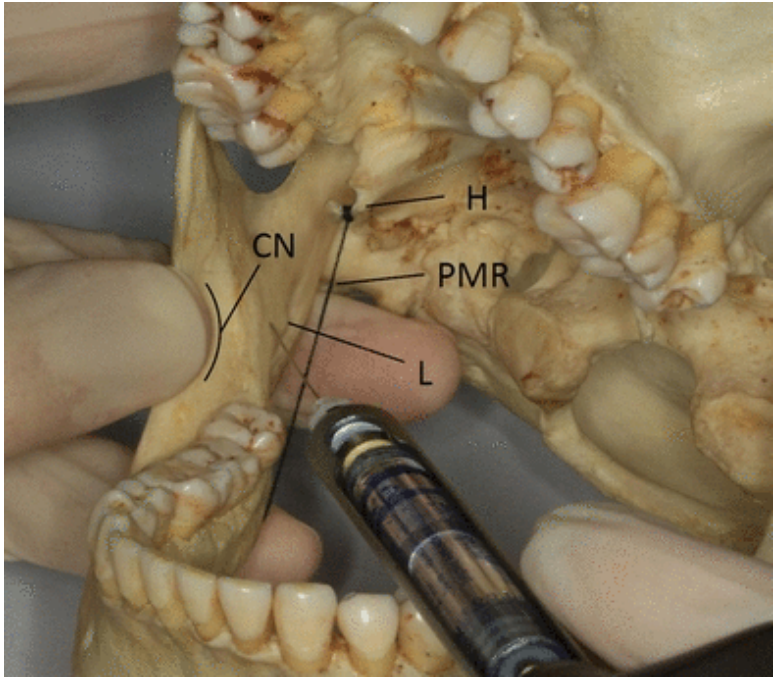

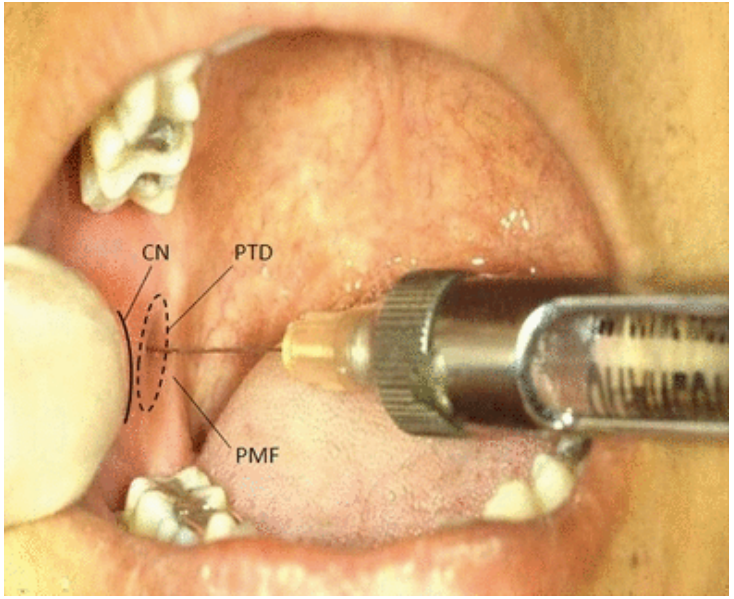

NYU Langone Health

Radiofrequency Ablation

- Continuous?
- Pulsed?

ELSEVIER

British Journal of Oral and Maxillofacial Surgery

Volume 50, Issue 1, January 2012, Pages e4-e5

Short communication

Pulsed radiofrequency modulation for lingual neuralgia

S.U. Rehman [a], M.Z. Khan [a], R. Hussain [b], A. Jamshed [c]

Show more

+ Add to Mendeley Share Cite

https://doi.org/10.1016/j.bjoms.2011.06.001

Get rights and content

Abstract

Pulsed radiofrequency modulation (PRM) is a minimally invasive procedure that has been used successfully to treat neuropathic pain. Its use to treat lingual neuralgia has not to our knowledge been described previously, and we report a case.

Neuromodulation

Neuromodulation of the lingual nerve: a novel technique

Christopher E. Talbot, DO,[1,2] Kevin Zhao, DO,[1,2] Max Ward, BS,[2] Aron Kandinov, MD,[2,3] Antonios Mammis, MD,[1,2] and Boris Paskhover, MD[2,3]

Departments of [1]Neurological Surgery and [3]Otolaryngology–Head & Neck Surgery, [2]Rutgers New Jersey Medical School, Newark, New Jersey

Acute injury of the trigeminal nerve or its branches can result in posttraumatic trigeminal neuropathy (PTTN). Affected patients suffer from chronic debilitating symptoms long after they have recovered from the inciting trauma. Symptoms vary but usually consist of paresthesia, allodynia, dysesthesia, hyperalgesia, or a combination of these symptoms. PTTN of the trigeminal nerve can result from a variety of traumas, including iatrogenic injury from various dental and maxillofa-
ulsed radiofrequency modulation, and microsurgical repair. Although
trigeminal neuropathy, V3 implantation is often avoided because of an
otion, and lingual nerve implantation has not been documented. Here,
efractory PTTN despite multiple alternative treatments. He elected
ulator for neuromodulation therapy. To the best of the authors' knowl-
erve stimulator implantation for lingual neuropathy, a technique for

; stimulation; burning mouth; face pain; surgical technique; peripheral

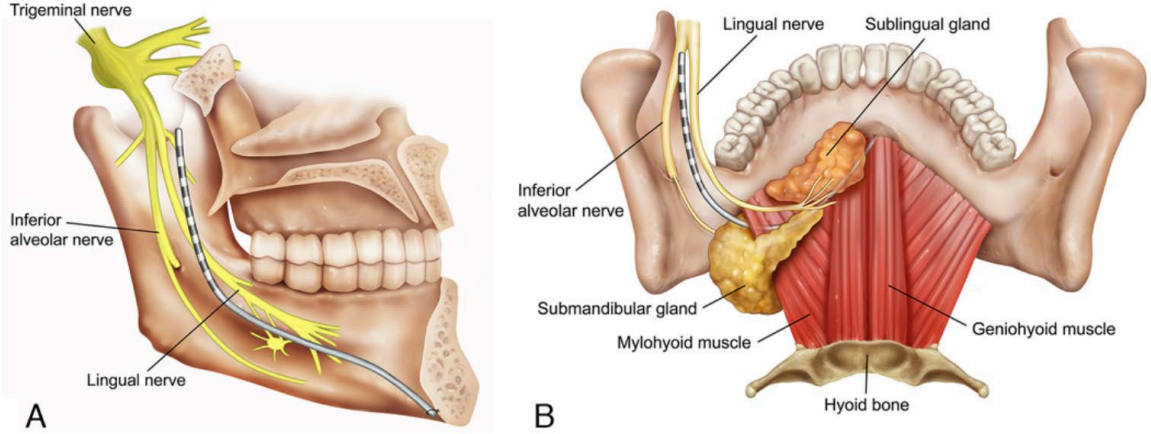

FIG. 1. Illustrations showing electrode placement from medial (**A**) and posterior (**B**) perspectives with labeling of anatomically significant structures. Copyright Boris Paskhover. Published with permission.

NYU Langone Health

References

- Garaycochea O, Baptista P, Calvo-Imirizaldu M, et al. Surgical anatomy of the lingual nerve for palate surgery: where is located and how to avoid it. *Eur Arch Otorhinolaryngol.* 2022;279(11):5347-5353.
- Khoury J, Mihailidis S, Ghabriel M, Townsend G. Applied anatomy of the pterygomandibular space: improving the success of inferior alveolar nerve blocks: Applied anatomy of the pterygomandibular space. *Australian Dental Journal*. 2011;56(2):112-121.
- Yates JM, Smith KG, Robinson PP. The effect of carbamazepine on injury-induced ectopic discharge in the lingual nerve. *Brain Research*. 2005;1051(1-2):1-7.
- Verweij JP, van Hof KS, Malessy MJA, van Merkesteyn R. Neuropathic pain due to iatrogenic lingual nerve lesion: nerve grafting to reduce otherwise untreatable pain. *Journal of Craniofacial Surgery*. 2017;28(2):496-500.
- Pogrel MA, Schmidt BL, Sambajon V, Jordan RCK. Lingual nerve damage due to inferior alveolar nerve blocks. *The Journal of the American Dental Association*. 2003;134(2):195-199.
- Boffano P, Roccia F, Gallesio C. Lingual nerve deficit following mandibular third molar removal: Review of the literature and medicolegal considerations. *Oral Surgery, Oral Medicine, Oral Pathology and Oral Radiology*. 2012;113(3):e10-e18.
- Rehman SU, Khan MZ, Hussain R, Jamshed A. Pulsed radiofrequency modulation for lingual neuralgia. *British Journal of Oral and Maxillofacial Surgery*. 2012;50(1):e4-e5.
- Robinson PP, Loescher AR, Yates JM, Smith KG. Current management of damage to the inferior alveolar and lingual nerves as a result of removal of third molars. *British Journal of Oral and Maxillofacial Surgery*. 2004;42(4):285-292.
- Bagheri SC, Meyer RA, Khan HA, Kuhmichel A, Steed MB. Retrospective review of microsurgical repair of 222 lingual nerve injuries. *Journal of Oral and Maxillofacial Surgery*. 2010;68(4):715-723.
- Talbot CE, Zhao K, Ward M, Kandinov A, Mammis A, Paskhover B. Neuromodulation of the lingual nerve: a novel technique. *Journal of Neurosurgery*. 2021;134(4):1271-1275.

NYU Langone Health

Questions

NYU Langone Health